Back in the Game

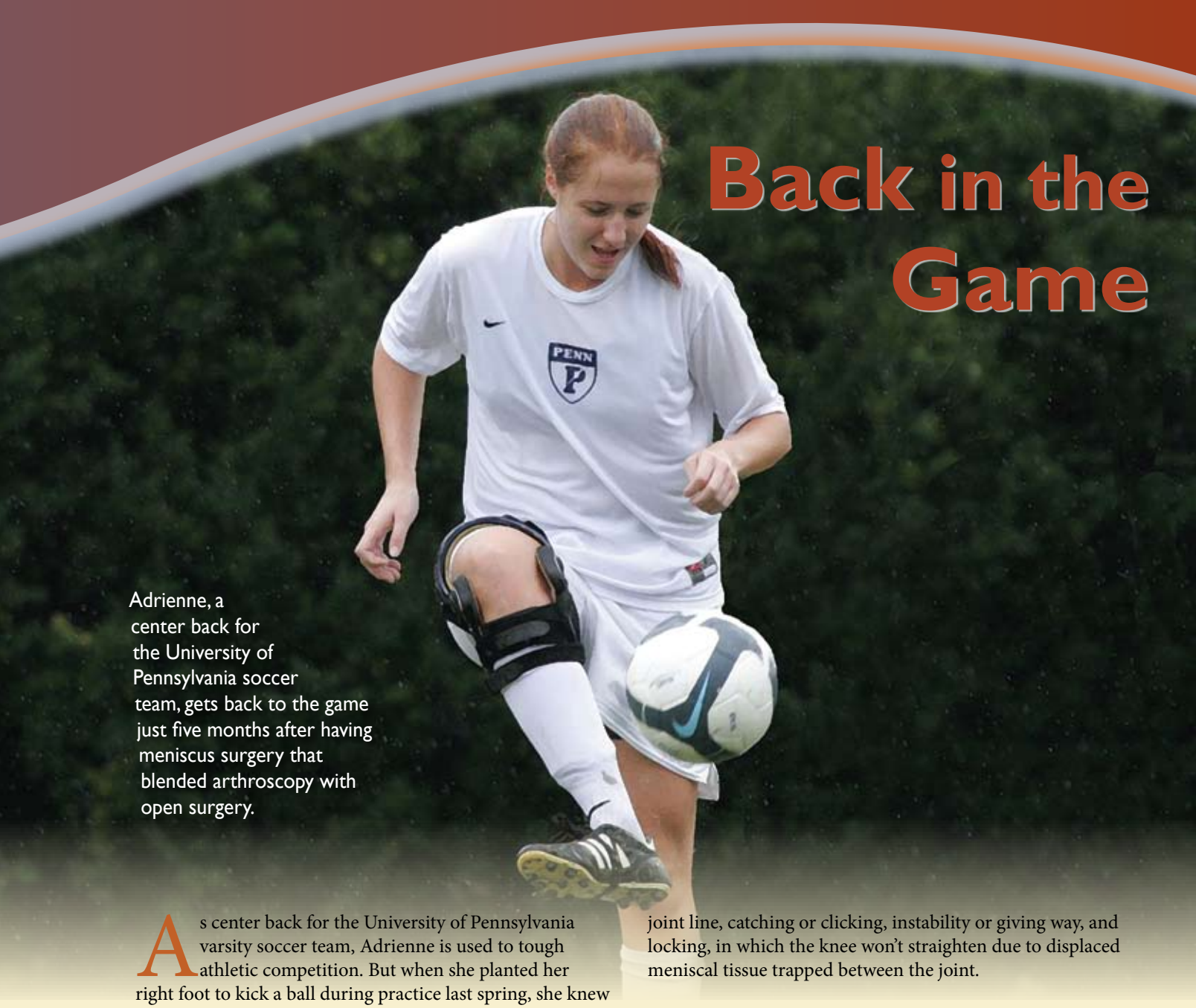

Adrienne, a center back for the University of Pennsylvania soccer team, gets back to the game just five months after having meniscus surgery that blended arthroscopy with open surgery.

As center back for the University of Pennsylvania varsity soccer team, Adrienne is used to tough athletic competition. But when she planted her right foot to kick a ball during practice last spring, she knew something was terribly wrong. "My leg gave out and I felt excruciating pain," recalls the 19-year-old, who is about to complete her sophomore year at Penn.

Adrienne had torn her meniscus, the rubbery, C-shaped disc that cushions the knee and helps distribute body weight across the knee joint. Meniscus tears are extremely common in young women athletes, and often occur together with injuries to the anterior cruciate ligament (ACL).

A torn meniscus can result from any activity that forcefully twists or rotates the knee, so athletes in high demand stop-and-go pivot sports are most vulnerable. Contact athletes, such as football players, may have added risk. But meniscus tears happen to people of all ages and activity levels. In older adults, the cause is usually degenerative changes of the knee. Symptoms include pain and swelling along the joint line, catching or clicking, instability or giving way, and locking, in which the knee won't straighten due to displaced meniscal tissue trapped between the joint.

Adrienne's injury was severe: her meniscus had shifted into the joint, she was in pain, and she couldn't straighten or bend her leg. Although treatment was available in Philadelphia, she opted to come home to Chevy Chase and have Thomas Klein, MD, care for her at Commonwealth Orthopaedics. Dr. Klein, who specializes in knee, hip, and shoulder procedures, had repaired Adrienne's ACL two years earlier. "He understands the pressures and challenges of being a Division I college athlete," Adrienne says. "We have a great relationship and I knew he could help me get back to soccer healthy and strong."

After discussing treatment options, they agreed on a repair technique that combined arthroscopy with open surgery. "At Commonwealth, we tailor treatment to the demands of each individual patient," Dr. Klein explains. "Those with smaller tears may have a completely arthroscopic procedure

Back in the Game

with tiny incisions—the very latest technique. For others like Adrienne, who want to return to high-level athletics as soon as possible, we use an older method that blends arthroscopy with open surgery. It's a little more complex, but it has a 95% success rate."

Because the meniscus aids in load transmission, stability, shock absorption, position, and movement, repair is the treatment of choice. But most tears are not repairable. In fact, the vast majority of Commonwealth patients—between 85 and 90 percent—have their meniscus removed rather than repaired.

"Treatment options depend on the type of tear, location, chronicity, and injury to other structures such as the ACL," says Robert Dombrowski, MD, who specializes in sports medicine, total joint replacement, and knee and shoulder surgery. "At Commonwealth, treatment ranges from conservative management, such as observation and activity modification, to operative management—either arthroscopic menisectomy to remove the damaged tissue, or open or arthroscopic repair."

Size and setting are critical factors in deciding whether to repair or remove a torn meniscus. "Repair is an option only when it's an outer rim injury where there is still blood flow to help with healing," says Dr. Klein. "When it's an inner edge tear, and there's no blood flow, it's like a hangnail. It will flap and flap and never heal, so we must remove it."

Arthroscopic repair techniques continue to evolve. One of the most promising is the Maxfire MarXmen™ meniscal repair system, which is the first of its kind to eliminate polymer and surface knots and protect the surrounding structures in the joint. Developed by Commonwealth Orthopaedics surgeon Keith Lawhorn, MD, in conjunction with Biomet Sports Medicine, the system mimics the gold standard inside-out suture repair constructs. "I've been using this for two years with great results," Dr. Lawhorn says. "Eliminating polymers and surface knots enhances the safety of the repair technique because there are no polymer- and knot-related complications to the joint."

Currently, there are several studies underway exploring the use of platelet-rich plasma (PRP) to augment the healing of meniscal repairs. In PRP therapy, a patient's own blood components are injected directly into damaged tissue, enhancing the body's natural healing process and accelerating recovery. (see related article on page 10) It is unclear if PRP will prove beneficial to healing of meniscal tear repairs as data from the studies involving meniscus injuries are not yet available.

Meniscal transplantation remains an option for younger patients with preserved joint surfaces but with pain due to a meniscal deficient compartment. Patients must have a stable knee with no ligamentous deficiency (ie: ACL tear) and normal alignment. Careful patient selection has resulted in improved short-term functional outcomes in these patients with significant loss of meniscal function. Long term results with regards to the prevention of knee osteoarthritis in these carefully selected patients have not yet to be proven and therefore must be considered a salvage intervention. Preservation of meniscal function of the patient's own meniscal tissue is always preferable if possible. Dr. Lawhorn will chair an instructional course on this trend at the 8th Biennial International Society of Arthroscopy Knee Surgery and Sports Medicine Congress in Brazil next year.

Following her meniscus repair last April, Adrienne spent the summer in physical therapy rebuilding her strength and stability. She progressed from walking on flat surfaces to biking, and then began running at the end of July. By mid-August she was back at school, taking part in technical drills with the Penn soccer team. One month later she was cleared to start contact play. On the final weekend of September, just five months after her surgery, she took the field in the Penn-Harvard game, and she's been playing ever since. "I completely trusted Dr. Klein's opinion and ability," she says. "My knee healed beautifully and I was able to get back on the soccer field safely. He had my best interests at heart."

Adrienne credits her orthopaedic surgeon for her quick return to playing Division I soccer, "I completely trusted Dr. Klein's opinion and ability."

Robert M. Dombrowski, MD, *received a BA in Biology from Washington and Jefferson College before going on to Case Western Reserve University in Cleveland, Ohio, where he earned his medical degree. He then completed his surgical internship and residency training in orthopaedic surgery at Georgetown University in Washington, DC.*

Thomas J. Klein, MD, *earned a BA in biology from Washington and Jefferson College before going on to graduate from medical school at Georgetown University School of Medicine. He completed his surgical internship in Danville, Pennsylvania, and did an orthopaedic surgery residency at Georgetown University Medical Center.*

Keith W. Lawhorn, MD, *graduated with a BA in Chemistry from the University of Virginia and continued his education at the University of Virginia School of Medicine, where he earned his medical degree . He completed a general surgery internship and orthopaedic residency at the Medical College of Virginia. Dr. Lawhorn served on active duty in the U.S. Air Force for eight years, reaching the rank of Lt. Colonel.*

For full biographies and a complete directory of the physicians at Commonwealth Orthopaedics who perform these and other procedures visit our website at ***www.c-o-r.com.***