1082-3131/99 $8.00 + .00

Lateral Epicondylitis

Keith A. Glowacki, MD

Lateral epicondylitis, also known as *tennis elbow,* is a common and well-known disorder caused by a pathologic condition of the common extensor origin at the lateral epicondyle of the humerus. It was originally described by Runge in 1873 as *writer's cramp.* There has been much controversy and little agreement in the literature regarding its pathogenesis, etiology, treatment, and natural course. It is common among workers (especially carpenters), musicians, and racquet-sport athletes. The incidence of tennis elbow in the general population varies from 1% to 3%. The incidence may be as high as 50% in recreational tennis players during their careers. The usual age of onset is 40 years (range 30 to 50 years).

Patients are usually categorized into one of two groups. There is a sports-related group, usually younger, and a repetitive-trauma, work-related group, usually older. The sports-related type is usually associated with a racquet sport in which abnormal stresses are placed across the extensor origin in different phases of the swing. The older work-related group is often chronic in nature and represents an accumulation of microtrauma to the extensor origin. The incidence in the work population is low (0.59%). The incidence among tennis players is high (between 40% and 50%).[7]

BACKGROUND

There are many causes for lateral elbow pain, including insertional tendinitis and microtrauma to tendon, entrapment of the radial nerve (radial tunnel sydrome), and possible intra-articular pathology.[12] One pathologic finding common to all conditions termed *lateral epicondylitis* is an abnormality of the tendon tissue in the region of the extensor carpi radialis brevis (ECRB). These changes may also be seen occasionally in the extensor digitorum communis and extensor carpi ulnaris. Repetitive microtrauma to the muscle origin leads to small tears. These heal through fibrosis, scarring, and granulation tissue. This may begin as a gradual process that then leads to mucinoid degeneration at the tendinous origin. This material is unable to withstand the stress normal tendon can and continues to tear. This eventually may lead to a rupture of the muscle origin.

From The Medical College of Virginia, Advanced Orthopaedic Centers, Richmond, Virginia

Gross inspection reveals edema and a homogeneous grayish-yellow tissue. Nirschl[6,7] used the term *angiofibroblastic hyperplasia* to describe the vascular compromise occurring at the tendon origin. The tissue reveals fibroblastic invasion and vascular ingrowth by microscopic analysis. Regan also noted focal hyaline degeneration at the tendon origin.[11] Goldie[4] was the first to describe these pathologic changes. He used longitudinal incisions to assess the tissues in a more detailed fashion. Nirschl and Pettrone[6] found these changes in 97% of their surgical cases as well as a rupture of the extensor brevis tendon in 35%. Goldie[4] also proposed the possibility of neuroma-like elements in the tissue. No studies have confirmed his proposal.

A small subset of patients develop a generalized tendinitis. This subset may have rotator cuff tendinitis, medial and lateral tennis elbow, carpal tunnel syndrome, trigger fingers, and de Quervain's tenosynovitis. This syndrome was initially reported in 1969 and was called the *mesenchymal syndrome*.[8]

Microscopically one finds a loss of the normal organized tendon tissue replaced by invading fibroblasts and a vascularized granulation-like tissue. Immediately adjacent to these areas, one encounters disruption of collagen and degeneration. There are many studies to support these pathologic findings.[3,4,11,12] It is highly unusual to detect inflammatory cells in the tendinous tissue, which has led some to suggest the term *tendinitis* be replaced by *tendinosis*, as recommended by Nirschl.[7]

DIAGNOSIS

Lateral epicondylitis can be differentiated from other lateral elbow abnormalities, such as arthritis, radiocapitellar synovitis, radial tunnel syndrome, and lateral elbow instability, by careful physical examination. The patient exhibits pain at the lateral elbow exacerbated by resisted wrist extension or with activities requiring wrist extension. The pain localizes to the origin of the extensor musculature on the lateral epicondyle. The ECRB origin is slightly anterior to the lateral epicondyle and is typically the site of maximum tenderness. Differentiation from radiocapitellar degenerative joint disease can be made by placing axial stress along the forearm with the wrist in neutral. As the joint is compressed, pain is reproduced. This indicates an arthritic joint process rather than a tendinous one. Lateral epicondylitis also may be associated with elbow stiffness upon awakening. Occasionally there is pain radiating along the dorsal aspect of the forearm into the long and ring fingers.

Radial tunnel syndrome may be associated with lateral epicondylitis. The character and location of the pain and provocative testing are the keys to differentiating radial tunnel syndrome from tennis elbow. A deep and more generalized pain exists in radial tunnel syndrome. The location of pain in radial tunnel syndrome is distal to the lateral epicondyle at the proximal edge of the supinator near the Arcade of Frohse. This muscle, when tested with resisted supination, compresses the posterior interosseous nerve and reproduces the patient's pain. Electrodiagnostic studies are frequently negative in radial tunnel syndrome. The diagnosis is usually based on clinical examination. Its status as a pathologic condition is still questioned by some.

Routine standard radiographs of the elbow should be obtained to look for calcifications or an exostosis in the region of the extensor origin. Degenerative changes in the radiocapitellar joint also may be found on radiographs.

TREATMENT

Conservative Treatment

Initial management of lateral epicondylitis should include activity modification. Those activities that exacerbate symptoms should be altered or avoided for a short

period of time. Nonsteroidal anti-inflammatory medications are routinely prescribed. For those with sports-related symptoms, adjustments can be made to the grip size and racquet weight. Specific exercises are recommended, focusing on stretching and appropriate warm-up prior to competition. For the workers' compensation patient, modified duty may help in reducing the acute symptoms.

Gellman has recommended a 20° wrist extension splint to be used during the initial treatment period of 4 to 6 weeks.[3] Gentle active and passive range-of-motion exercises of the elbow and wrist are prescribed. These should not reproduce symptoms.

Cortisone injections also are performed for those who are unresponsive to initial treatment. A mixture of a corticosteroid and lidocaine in combination with oral anti-inflammatories and splinting can be used. The lidocaine–steroid injection is placed in the region of the point of maximum tenderness, avoiding a superficial injection, which could lead to subdermal atrophy and depigmentation.[10] There is a generalized agreement that there should be no more than three injections within 12 months.[3,5,7,10,12] Price found no long-term difference between a simple injection of lidocaine and that of lidocaine and a steroid.[10] However, he did demonstrate an improved early response when the steroid was included. A topical anesthetic is recommended prior to the corticosteroid injection. A gentle, slow introduction of the material in the region of the ECRB is then performed. Following the injection, the patient is reevaluated to see if symptoms have improved. Patients should be told to place ice for 20 minutes to an hour on the day of the injection to minimize any inflammatory reaction after the injection.

Despite all the recommendations to perform cortisone injections, there is no definitive prospective study demonstrating the long-term efficacy of cortisone injections in treating tennis elbow.

Nirschl has proposed counterforce bracing as a splinting modality to help in treating lateral epicondylitis.[6] The concept is a distribution of the normal forces in the surrounding tissues over a larger surface area, thereby decreasing the total amount of force seen at the ECRB tendon and common extensor origin. This has been shown to reduce various muscle forces seen at the elbow during tennis and with isometric contractions. Nirschl also has recommended the use of electrical stimulation.[7] Other therapeutic modalities include cold therapy (reduces swelling and pain by elevating the pain threshold and slowing nerve conduction), application of heat (produces an analgesic effect also by elevating the pain threshold), electrical stimulation (current across the tissues produces effect of warming), and iontophoresis (uses electrical stimulation to drive ion-charged medications through the skin and subcutaneous tissues to the deeper muscle and tendon). In the latter modality, corticosteroids are routinely used. There is no definitive proof of the efficacy of this treatment. Early range of motion and an appropriate exercise program follow the acute management. This includes instructions on appropriate stretching and warm-up exercises. Appropriate restrictions for work-related activities followed by progressively reducing the restrictions over a 4- to 6-week period are recommended. This should be followed by a conditioning program that attempts to strengthen and return the extremity to its preinjury state.

Surgical Treatment

Many surgical procedures are available for the treatment of lateral epicondylitis. In general, most produce satisfactory results 85% of the time. These procedures can be divided into three different categories: anatomic tendon architecture-preserving procedures, tendon-releasing procedures, and joint-related procedures. Specifically, Boyd and McLeod reported a modification of the Bosworth procedure that includes an elbow arthrotomy with synovectomy, release of the extensor origin, and excision of a portion of the annular ligament.[1,2] This procedure combines a tendon-releasing procedure with a joint exploration and synovectomy to help alleviate pain that may

originate from within the elbow joint. Nirschl and Pettrone débrided the abnormal tissue via a longitudinal tenotomy. This was followed by a bony abrasion at the site to stimulate ingrowth and tendon attachment.[6] This represents a tendon-preserving procedure via a longitudinal tenotomy. The substance of the tendon is preserved by removing only the abnormal tissue and leaving much of the fibers intact. Posch showed satisfactory results with a simple fasciotomy of the common extensor tendon from its origin.[9] Unlike Nirschl's procedure, this detaches the tendon without preserving longitudinal fibers. Although this has been reported to be successful, some strength could be lost in wrist extension. Percutaneous release has been shown to be effective though only with short-term follow-up. A transverse tenotomy of the ECRB has been shown to be effective as well. There is also concern regarding loss of grip strength with this tenotomy. These procedures may be combined with intra-articular partial or complete division of the annular ligament and/or synovectomies.[1,2,3,5,6,9,12] The majority of these procedures are successful if there is a detachment of the ECRB origin from the lateral epicondylar ridge. The procedure that preserves the most normal anatomic architecture is that proposed by Nirschl and Pettrone.[6]

Patients who have failed conservative management within 1 year, with a special subset including highly competitive athletes, are candidates for surgical intervention. The competitive athlete group shows a higher incidence of actual tendon rupture. An earlier approach to surgical management is recommended in these patients.

It can be difficult to determine which surgical candidates would benefit from a procedure. Several important points may aid in choosing operative candidates. A bone scan should show increased activity around the lateral epicondylar region if true epicondylitis exists and has been resistant to conservative measures. Patients who have had multiple cortisone injections are more likely to have degenerative tissue and tendon abnormalities that do not respond to therapy and splinting. A gun-site lateral radiograph of the distal humerus may reveal a traction osteophyte in the region of the lateral epicondyle. This indicates a longer duration of disease that may likely fail conservative treatment. Finally, compliance in a supervised therapy program prior to surgical intervention is critical.

It is important to distinguish posterior interosseous nerve compression from isolated epicondylitis. Five percent of patients with lateral epicondylitis are reported to have radial tunnel syndrome.[13] There are some who feel the spectrum of disease of lateral epicondylitis includes, in a more chronic and long-standing case, the development of radial tunnel syndrome.

Surgical Technique

The operation is usually performed on an outpatient basis. Anesthesia is most commonly regional axillary block or local anesthesia with intravenous sedation. If a combined radial tunnel release is performed, general or regional anesthesia is recommended. A nonsterile arm tourniquet is used along with a single dose of prophylactic antibiotics. A skin incision over the lateral aspect of the elbow that extends from one finger-breadth above the lateral epicondyle to the radial head distally is used (Fig. 1).

Figure 1. Skin incision.

Branches of the lateral antebrachial cutaneous nerve are identified and protected. Hemostasis is obtained with bipolar cautery. The interval between the extensor aponeurosis and the extensor carpi radialis longus is identified. Following identification of the extensor aponeurosis, a longitudinal incision is made parallel to the skin incision. This incision extends between the extensor longus and the extensor aponeurosis (Fig. 2).

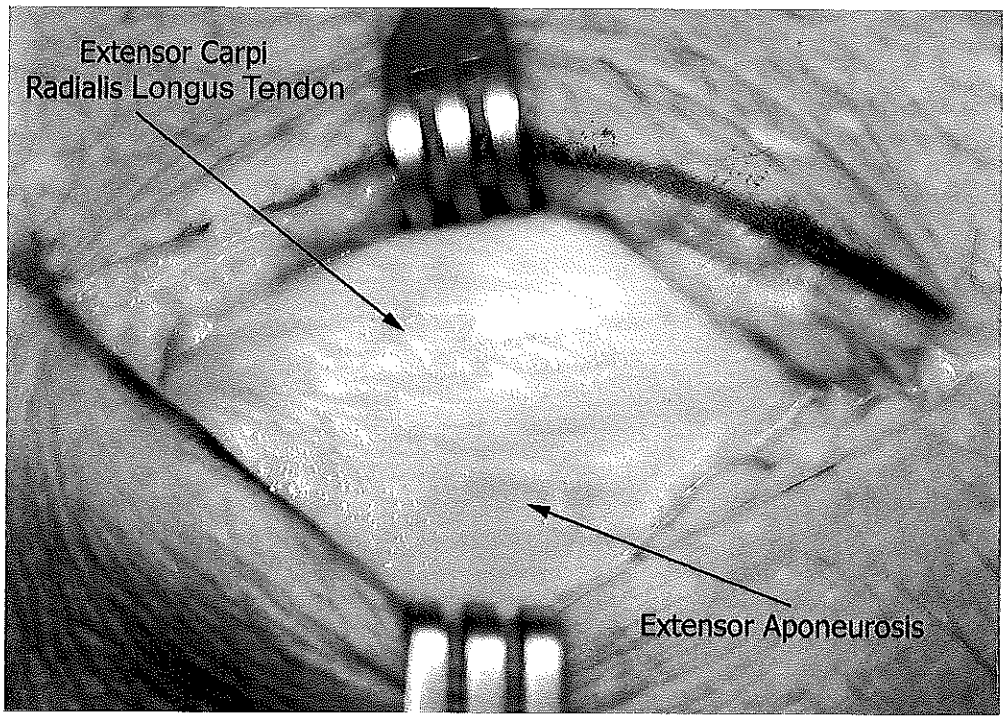

Figure 2. Outer fascial layer includes extensor longus tendon and extensor aponeurosis.

Careful blunt dissection of the muscle fibers of the extensor longus beneath this incision reveals the fascia of the ECRB. Anterior retraction of the extensor longus tendon exposes the origin of the ECRB (Fig. 3).

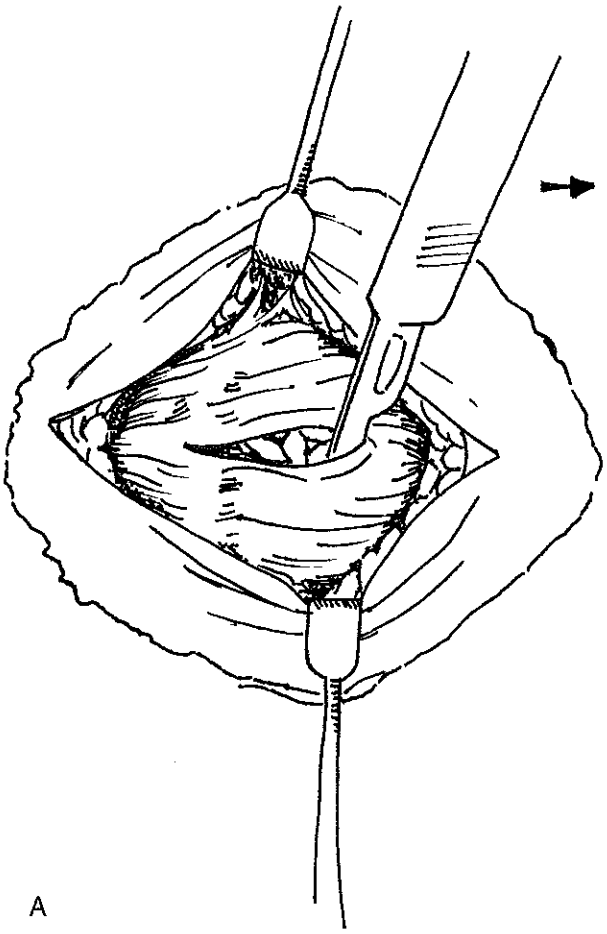

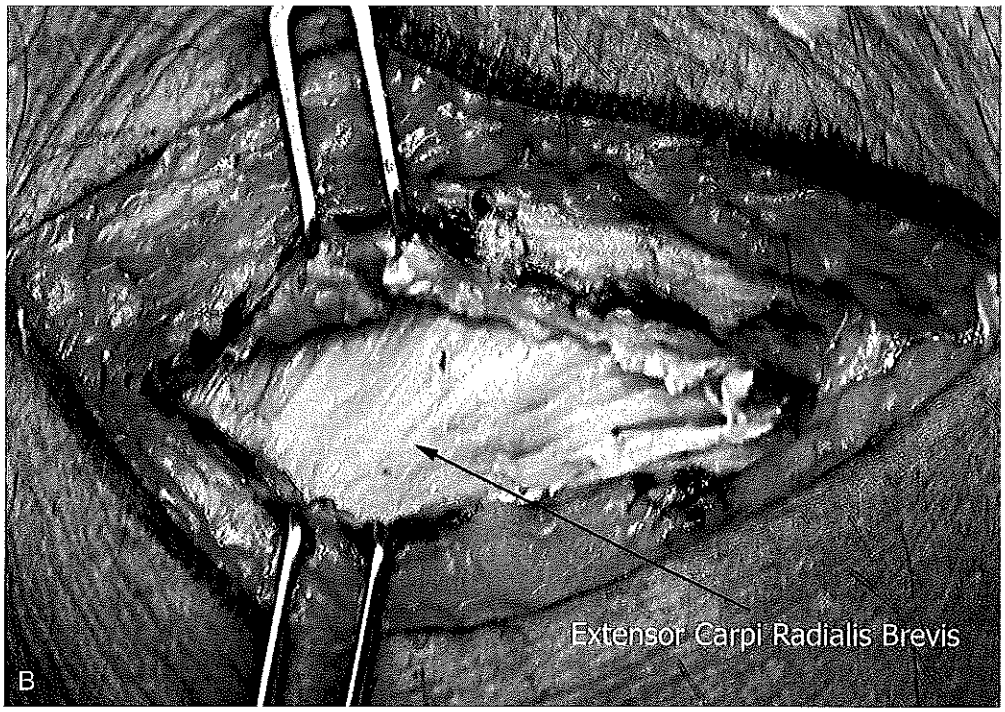

Figure 3. *A,* Longitudinal split to reveal ECRB tendon origin. Extensor origin 2 to 3 mm thick at this point. *B,* Incision extends between interval of extensor longus and aponeurosis. Anterior retraction reveals ECRB origin and pathologic tissue.

Preservation of the extensor brevis relation between the orbicular ligament and the fascia prevents distal retraction of the extensor origin. This minimizes the potential for any decrease in strength secondary to altering muscle length. The pathologic tissue is then excised back to normal tendinous tissue (Figs. 4 and 5).

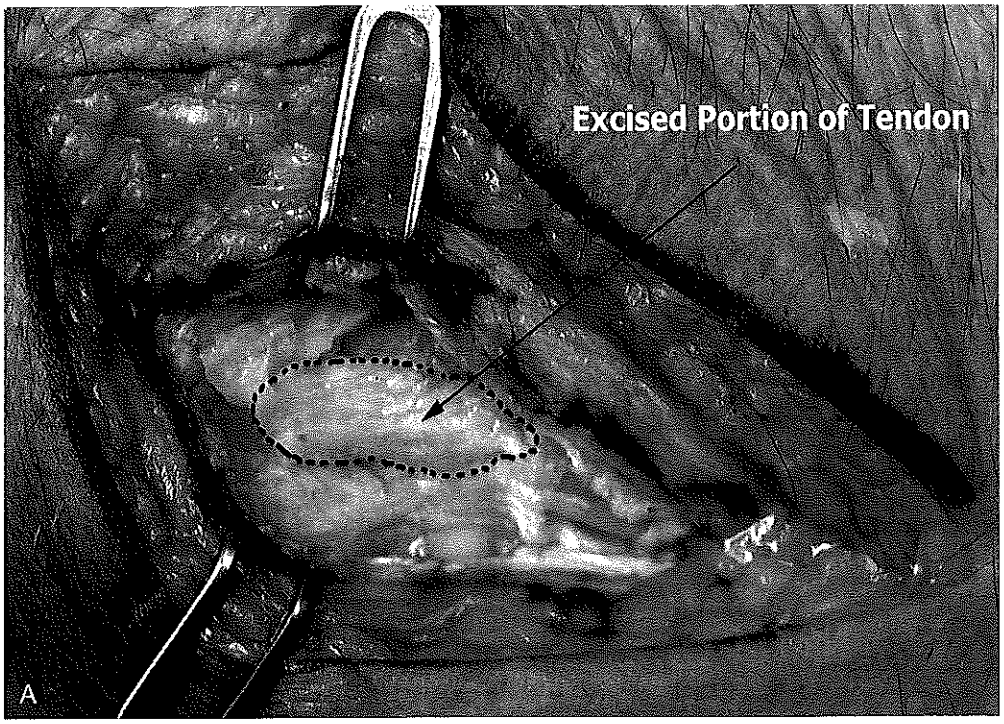

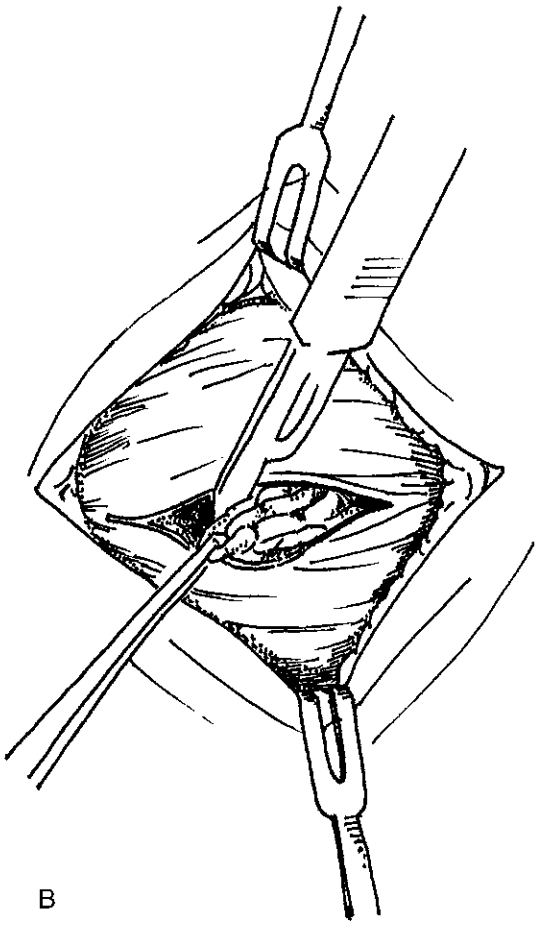

Figure 4. *A,* Dashed area indicates ECRB to be resected. *B,* Resection is done sharply with a scalpel. Care is taken not to penetrate into the joint.

Figure 5. Extensor brevis origin resected and lateral epicondylar ridge exposed. A small inferior arthrotomy to examine the radiocapitellar joint can be performed. This is closed after inspection.

Care is taken to avoid entering the elbow joint. If the joint is entered, the capsule should be closed with absorbable sutures to avoid postoperative ganglion formation.

The pathologic tendon tissue includes most of the ECRB and, infrequently, part of the common extensor origin. It is critical to remove all pathologic tissue and, at times, the area involved may be rather large. This is usually done sharply with a #69 Beaver blade (Becton-Dickinson, Franklin Lakes, NJ.) Beneath this tissue defect, the lateral epicondylar bone is decorticated to enhance the blood supply to the tendon (Fig. 6).

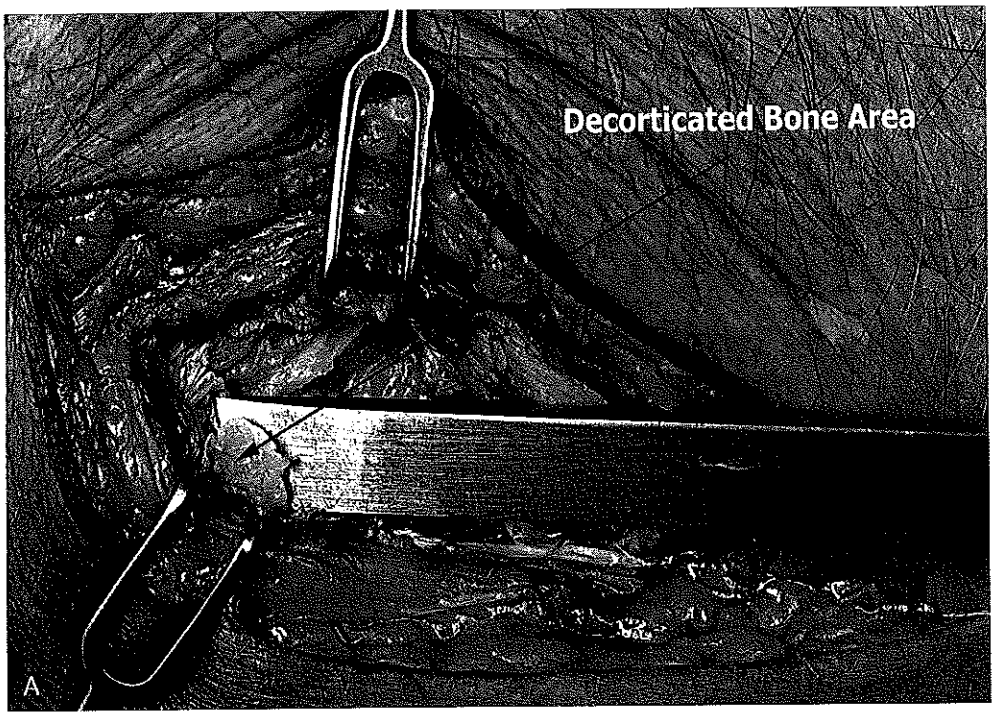

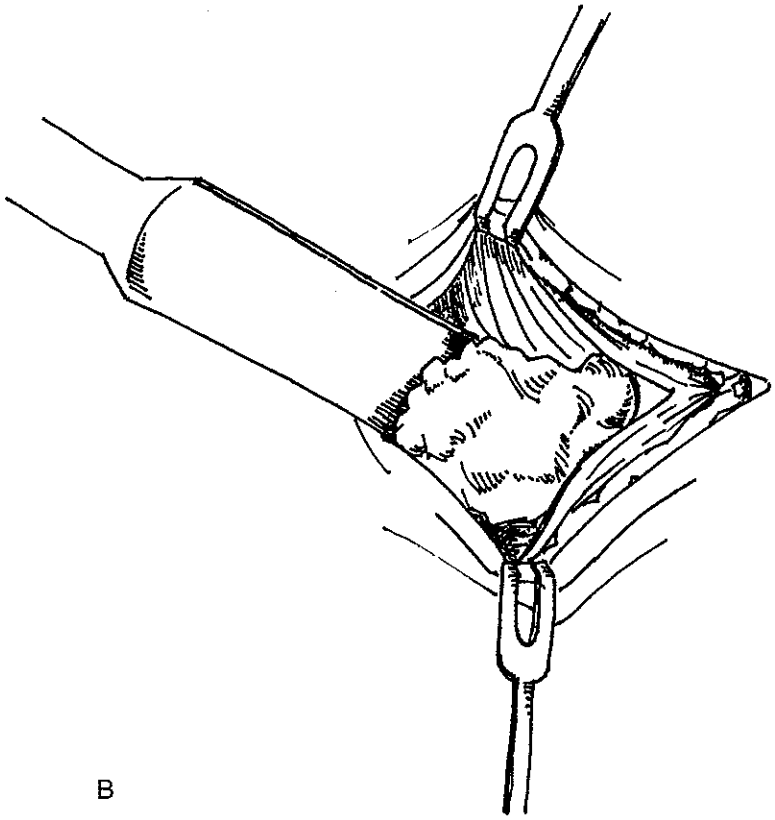

Figure 6. *A,* Osteotome decorticates to expose cancellous bone. This allows for better tendinous healing. *B,* Decorticate or drill holes to provide vascular enhancement. (Drill 3 to 4 holes with 0.035 K-wire.)

This can be performed by drilling multiple holes or by using a small rongeur. Any calcifications in the soft tissues are removed at this time over the lateral epicondyle. The remaining defect is closed with a #1 absorbable suture. Reapproximating the posterior edge of the ECRL to the anterior edge of the extensor aponeurosis recreates an anatomic repair (Fig. 7).

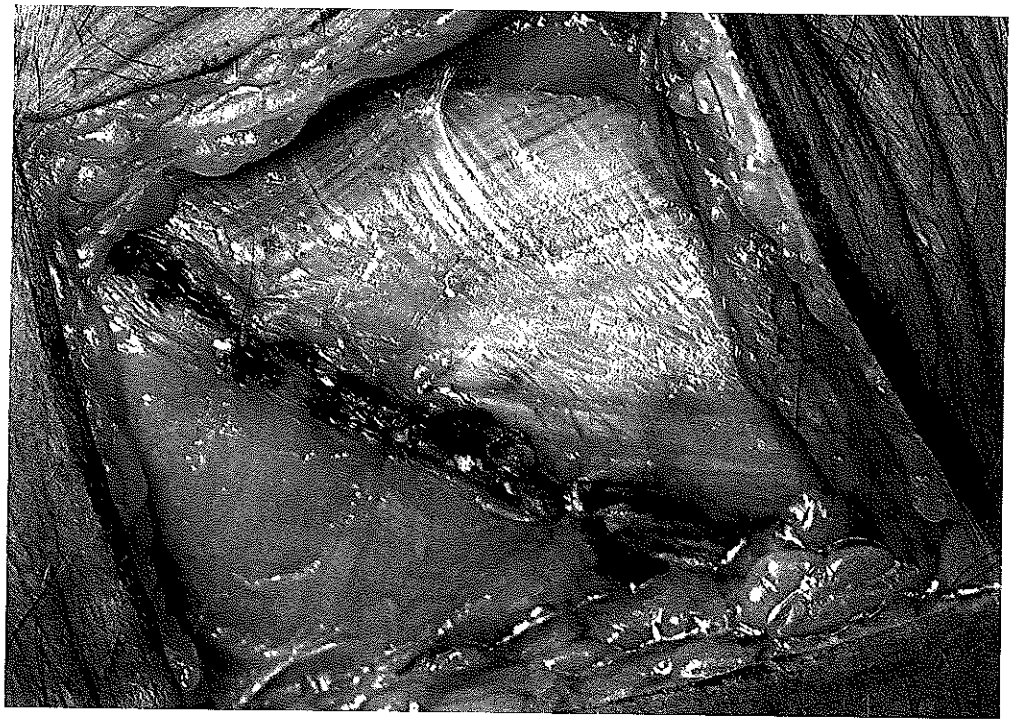

Figure 7. Closure of extensor longus/aponeurosis interval.

A small vessel loop drain can be maintained subcutaneously in the wound and pulled out later. This prevents a postoperative hematoma without the need for a suction drain. The tourniquet also can be let down to obtain adequate hemostasis. The author prefers to leave the tourniquet elevated until the dressing is applied because the exposed bone surface tends to bleed. A soft dressing with a long arm posterior elbow plaster splint is applied. Using bulky fluffs with padding circumferentially around the elbow, one can allow for adequate compression without constriction.

POSTOPERATIVE CARE

After 10 to 12 days, the splint is taken down, sutures are removed, and Steri-Strips are applied. A therapy program consisting of range-of-motion exercises for the elbow, wrist, and forearm is begun. A sling can be used at this point to maintain the elbow when not performing range-of-motion exercises. Once full range of motion is achieved (usually 4 to 6 weeks), a gentle strengthening program with light repetition is begun. The wrist should be splinted for the first several weeks to prevent overuse of the common extensors. The strengthening exercises are gradually increased to include endurance training and work simulation. For those playing sports, gentle strokes can be performed at 6 weeks. At 3 months, a higher level of activity can be performed with tennis and racquet sports. It is typically 6 months before one can engage in competitive sports and heavy demand labor.

COMPLICATIONS

Morrey has classified surgical failures into two types.[5] A type I failure has similar symptoms before and after surgery. The causes may be inappropriate patient selection, incomplete diagnosis, and/or an incomplete release or excision of tissue. Excessive resection of the annular ligament may lead to elbow instability. There may be associated posterior interosseous nerve entrapment or unrecognized radiocapitellar arthrosis. Posterior interosseous nerve compression can be diagnosed by performing an injection of the posterior interosseous with relief of pain differentiating from a lateral epicondylar injection relieving pain.

Type II failures have different postoperative symptoms. These may include lateral antebrachiocutaneous neuromas, inadvertent joint fistula formation, and/or lateral ligament resection.[5] Treatment includes reconstruction of the unstable ligaments, decompression of the posterior interosseous nerve, resection and closure of the capsule, or fistula formation.

CONCLUSION

Surgical treatment of lateral epicondylitis has been proven a reliable technique with a success rate of more than 85%. Many operative procedures have been described with similar reported results. After exhausting appropriate conservative measures, surgical treatment of selected patients is recommended consisting of resection of all abnormal tendinous tissue, anatomic repair, and supervised postoperative therapy. This leads to satisfactory results in most cases.

References

1. Bosworth DM: The role of the orbicular ligament in tennis elbow. J Bone Joint Surg Am 37: 527–533, 1955
2. Boyd HD, McLeod AC Jr: Tennis elbow. J Bone Joint Surg Am 55:1183–1187, 1973
3. Gellman H: Tennis elbow (lateral epicondylitis). Orthop Clin North Am 23:75–82, 1992
4. Goldie I: Epicondylitis lateralis humeri: A pathogenetical study. Acta Chir Scand (Suppl) 339, 1964
5. Morrey BF: Surgical failure of the tennis elbow. *In* Morrey BF (ed): The Elbow and Its Disorders, 2nd ed. Philadelphia, WB Saunders, 1993, pp 553–559
6. Nirschl RP, Pettrone FA: Tennis elbow: The surgical treatment of lateral epicondylitis. J Bone Joint Surg Am 61:832–839, 1979
7. Nirschl RP: Muscle and tendon trauma: Tennis elbow. *In* Morrey BF (ed): The Elbow and Its Disorders, 2nd ed. Philadelphia, WB Saunders, 1993, pp 537–547
8. Nirschl RP: Mesenchymal syndrome. Va Med Q 96:659–664, 1969
9. Posch JR, Goldberg VW, Lavrey R: Extensor fasciotomy for tennis elbow: A long-term follow-up study. Clin Orthop 135:179–182, 1978
10. Price R, Sinclair H, Heinrich I: Local injection treatment of tennis elbow: Hydrocortisone, triamcinolone, and lignocaine compared. Br J Rheumatol. 30:39–44, 1991
11. Regan W, Wold LE, Coonrad R, et al: Microscopic histopathology of chronic refractory lateral epicondylitis. Am J Sports Med 20:746–752, 1992
12. Verhaar J, Walenkamp G, Kester A, et al: Lateral extensor release from tennis elbow. J Bone Joint Surg Am 75:1034–1043, 1993
13. Werner CO: Lateral elbow pain and posterior interosseous nerve entrapment. Acta Orthop Scand Suppl 174:1–16, 1979

Address reprint requests to

Keith A. Glowacki, MD
Medical College of Virginia
Advanced Orthopaedic Centers
7650 E. Parham Road
Richmond, VA 23294