# Vascular Leiomyoma of the Finger Causing Bone Erosion

Keith A. Glowacki, MD, Arnold-Peter C. Weiss, MD, Providence, RI

The vascular leiomyoma, or angiomyoma, is a benign tumor that most commonly presents in the lower extremity. Previous studies by Neviaser and Newman have shown that its occurrence in the upper extremity may be higher than originally thought.[1] Over an 18-year period, they found 12 of 85 cases occurring in the hand. To our knowledge, previous reports have not demonstrated any associated involvement of the bone or tendon sheath.[1-5]

## Case Report

A 73-year-old right-hand dominant man presented with a 3-year history of a slowly enlarging, painless mass at the palmar aspect of his right index proximal phalanx. No history of trauma or other lesions were noted.

On physical examination, a $3 \times 2 \times 1$ cm firm, nontender, multilobulated mass could be easily palpated. Distal neurovascular examination and range of motion were normal. X-ray studies revealed a soft tissue mass producing extensive bone changes in the palmar shaft of the proximal phalanx. These bone changes appeared consistent with a secondary pressure phenomenon by the tumor bulk as supported by a lack of periosteal reaction to the lesion and intact cortex of the remaining shaft (Fig. 1).

Under regional anesthesia, exploration revealed the tumor in the subcutaneous region extending in a horseshoe-shaped fashion between the flexor tendons and the proximal phalanx, but no direct connection to the digital arteries was noted (Fig. 2). The gross appearance was of a hemorrhagic, multilobulated mass with a rubbery consistency. A defect with intact, but significantly depressed, cortex was noted in the proximal phalanx upon removal of the entire mass. Bone grafting was not performed. Postoperative range of motion exercises were started at 5 days. At 2-year final follow-up examination, no recurrence was noted, finger range of motion was full, and the x-ray film contour of the phalanx had returned to normal.

Pathologic diagnosis was of a well-circumscribed vascular leiomyoma composed of vascular channels and bundles of smooth muscle (Fig. 3).

## Discussion

Leiomyomas are slowly growing tumors that can be painful. They can occur in the hand, wrist, and forearm, but are most frequently seen in the lower extremity. Patient presentation is most commonly in the fifth to seventh decades with no sex predominance. Surgical excision is the treatment of choice in all reported series.[1-3] Only one reported recurrence after excision, indicating the possibility of malignant degeneration, has been noted in the literature.[2]

Histologic examination demonstrates varying percentages of smooth muscle-type cells and vascular elements surrounded by a thin pseudocapsule. Of the three types of leiomyomas described (cutaneous multiple, solitary genital, and vascular), those occurring in the upper extremity are always of the vascular type. Arteriography may be beneficial in demonstrating involvement of the digital or palmar vasculature.

The bony erosion and adherence of the tumor to the flexor tendon sheath noted in this case are quite atypical. Despite significant bony erosion quantita-

From the Department of Orthopaedics, Brown University School of Medicine, Rhode Island Hospital, Providence, RI.

Received for publication Feb. 7, 1995; accepted in revised form May 8, 1995.

No benefits in any form have been received or will be received from a commercial party related directly or indirectly to the subject of this article.

Reprint requests: Arnold-Peter C. Weiss, MD, University Orthopedics, Inc., 2 Dudley Street, 2nd Floor, Providence, RI 02905.

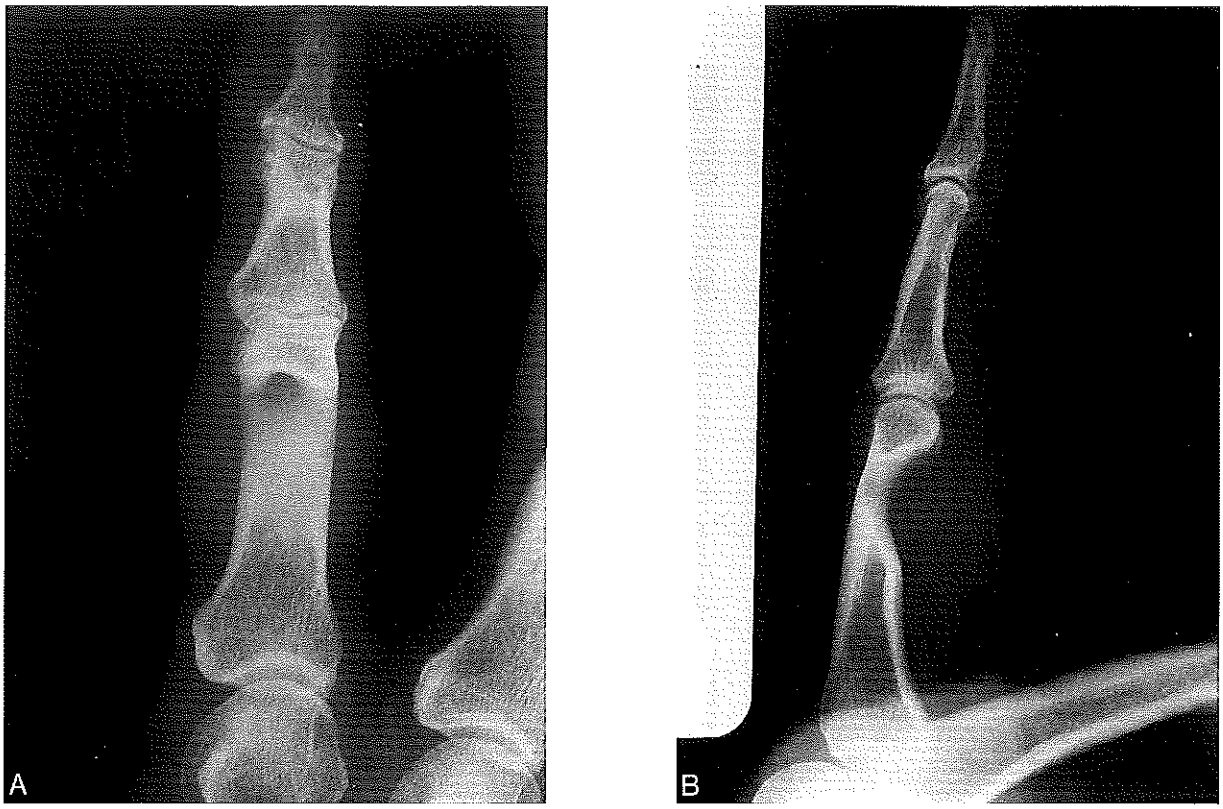


**Figure 1.** (A) Anteroposterior and (B) lateral x-ray films of the right index finger demonstrate substantial palmar bone erosion of the proximal phalanx without periosteal reaction.

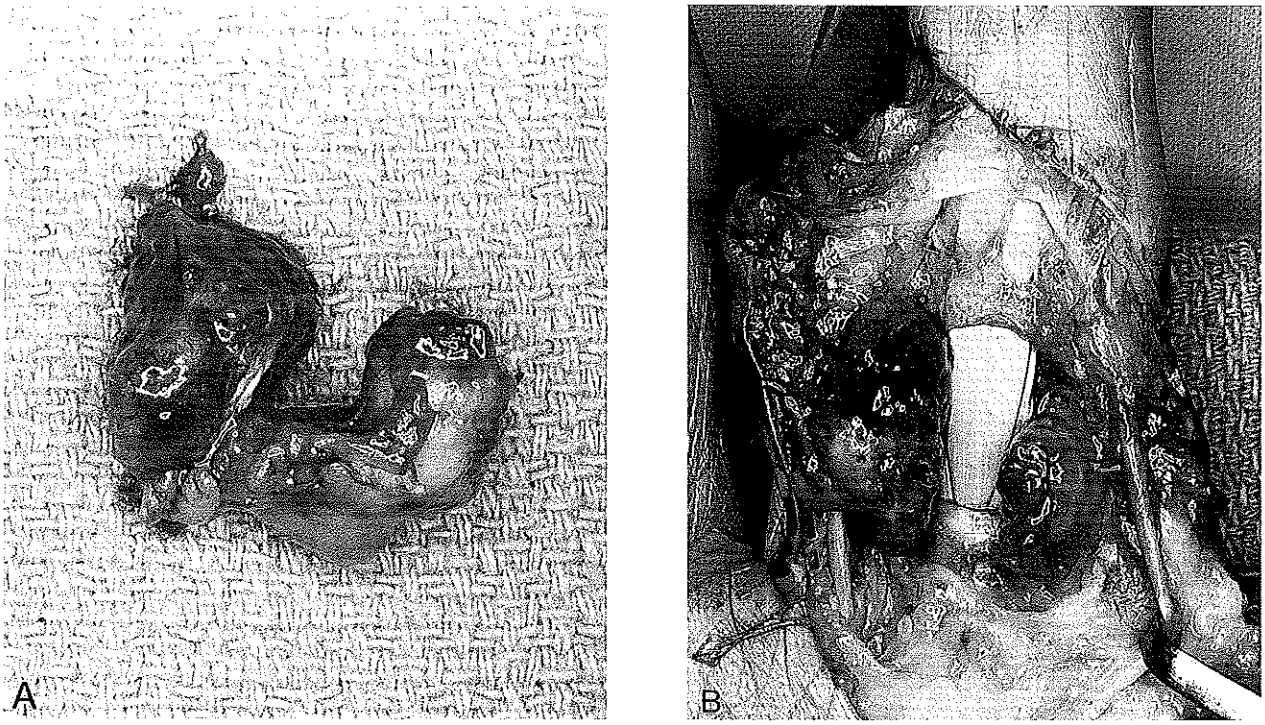


**Figure 2.** (A) The tumor was horseshoe-shaped coursing between (B) the flexor tendon and the proximal phalanx and was found to be densely adherent to the flexor sheath.

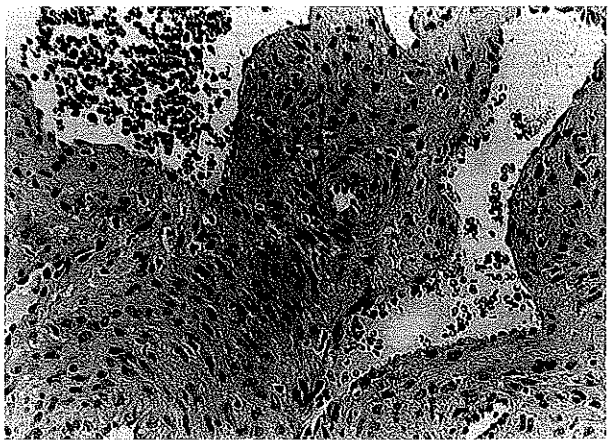

**Figure 3.** Photomicrograph demonstrating smooth muscle cells with some palisading interspersed between vascular channels. Mitotic figures are dispersed throughout the small muscle stroma (hematoxylin and eosin; original magnification × 250 ).

tively, the qualitative aspects of the phalanx were quite good, with excellent corticalization allowing for early range of motion exercises without undue risk of secondary fracture.

## References


1. Neviaser RJ, Newman W. Dermal angiomyoma of the upper extremity. J Hand Surg 1977;2:271–4.
2. Shapiro JD, Froimson AI. Angiomyoma in the hand. Orthopaedics 1988;11:1709–10.
3. Robinson SC, Kalish RJ. Leiomyoma in the hand. Clin Orthop 1990;255:121–3.
4. Duhig JT, Ayer JP. Vascular leiomyoma: a study of 61 cases. Arch Pathol Lab Med 1959;68:424–30.
5. Hauswald KR, Kasdan ML, Weiss DL. Vascular leiomyoma of the hand: case report. Plast Reconstr Surg 1975; 55:89–91.