Midfoot

Anish R. Kadakia, Paul J. Switaj, Bryant S. Ho, Mohammed Alshouli, Daniel Fuchs, and George Ochengele

1 Arthritis

Take-Home Message

- Primary osteoarthritis most common.
- Nonoperative management with a carbon fiber plate and midfoot rocker shoe modification is the first-line treatment strategy.
- Operative management consists of a tarsometatarsal arthrodesis with realignment in the cases of midfoot deformity (RA and chronic Lisfranc).
- Arthrodesis of medial and middle columns is effective and does not significantly adversely affect foot function.
- Arthrodesis of lateral column adversely alters foot function as it alters ground accommodation. Therefore, interpositional arthroplasty (tendon, implant, collagen matrix) has been advocated as an alternative treatment instead of arthrodesis for the 4th and 5th TMT joints.

Introduction

- Arthritis of the midfoot is a significant cause of pain and disability. Midfoot articulations include naviculocuneiform (NC) and tarsometatarsal (TMT) joints.

A.R. Kadakia, MD (✉) • P.J. Switaj • B.S. Ho • M. Alshouli • D. Fuchs • G. Ochengele
Department of Orthopedic Surgery, Northwestern University – Feinberg School of Medicine, Northwestern Memorial Hospital, Chicago, IL, USA
e-mail: Kadak259@gmail.com; paul.switaj@gmail.com; bryant.s.ho@gmail.com; mtshouli@gmail.com; dfuchs0011@gmail.com; gochenjele@gmail.com

© Springer-Verlag France 2015

C. Mauffrey, D.J. Hak (eds.), *Passport for the Orthopedic Boards and FRCS Examination*, DOI 10.1007/978-2-8178-0475-0_40

Etiology

- Primary osteoarthritis is the most common cause of hindfoot arthritis.
- Posttraumatic arthritis is second.
- Inflammatory.

Pathophysiology

- The middle column has limited motion but is exposed to large forces.
- Abnormally high forces through the midfoot lead to the incompetence of supporting soft tissue structures → joint subluxation → increased contact pressure → degeneration.
- Inflammatory processes and posterior tibialis tendon dysfunction (PTTD) can lead to midfoot collapse and arthritis.
- Gastrocnemius contracture will increase forces across the midfoot possibly accelerating the disease.

Radiography

- AP (1st, 2nd, 3rd, and N-C joints), oblique (3rd, 4th, and 5th TMT joints), and lateral WB radiographs:
  - Joint-space narrowing or loss (The lateral view may reveal joint-space narrowing not appreciated on the AP or oblique radiographs (Fig. 1))
  - Subchondral sclerosis/cysts
  - Osteophytes and bony erosions – best seen on lateral view
  - Disruption of Meary's line (loss of colinearity between talus and 1st MT) with apex deformity at midfoot and longitudinal arch collapse on lateral view
  - Forefoot abduction deformity. Critical to differentiate from PTTD flatfoot deformity where TN in abduction > TMT (Fig. 2)

Treatment

Nonoperative

- A stiff carbon fiber plate inserted underneath the insole of the shoe or a rocker-bottom shoe will offload stress on the midfoot during gait and may relieve mild degenerative symptoms.
- Rigid deformity should be managed with accommodative, not corrective orthotics that support and offload the deformity.
- Corticosteroid/anesthetic injections: both diagnostic (determine symptomatic joints) and therapeutic

Operative

Indication is failure of nonoperative with persistent pain and disability. Arthrodesis is the treatment of choice. Goal of surgery is to obtain solid fusion and restoration of normal foot alignment.

- Medial and middle column arthrodesis ensuring a normal anatomic alignment. Residual deformity will predictably result in a poor outcome (Fig. 3).

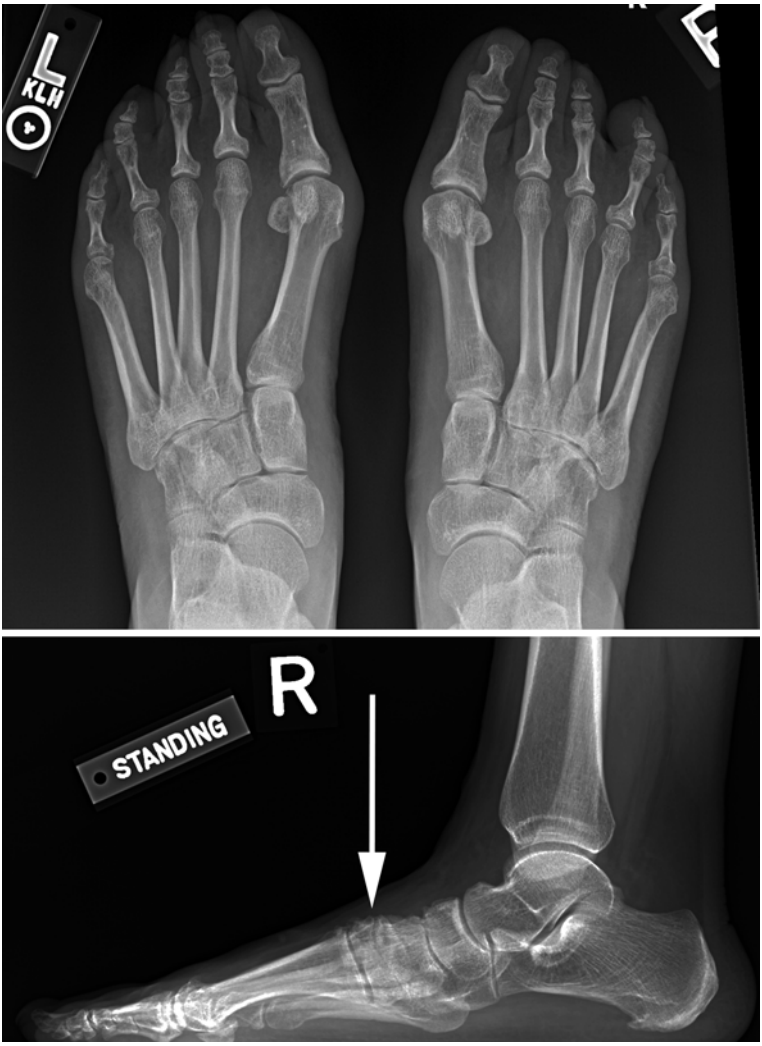

Fig. 1 Patient with midfoot arthritis primarily at the middle column. Note the subtle asymmetric narrowing on the AP radiograph. The presence of 2nd TMT degeneration is clearly seen on the lateral radiograph (*arrow*)

- Interpositional arthroplasty (motion sparring) of lateral column is preferred for symptomatic 4th and 5th TMT arthritis given the biomechanical advantage. However, no significant data is present to support motion-sparing procedures over arthrodesis.
- A simultaneous gastrocnemius recession and/or hindfoot osteotomy might be required to restore normal foot alignment (Fig. 4).

Fig. 2 AP WB radiograph demonstrating abduction deformity of the foot that is clearly focused at the TMT joints (*arrowhead*). Note the minimal amount of TN joint subluxation despite the severe deformity, indicating this is a midfoot driven flatfoot and not related to PTTD

Complications

- Nonunion/malunion
- Wound complications

Bibliography

1. Nemec SA, Habbu RA, Anderson JG, Bohay DR. Outcomes following midfoot arthrodesis for primary arthritis. Foot Ankle Int. 2011;32(4):355–61.
2. Patel A, Rao S, Nawoczenski D, Flemister AS, DiGiovanni B, Baumhauer JF. Midfoot arthritis. J Am Acad Orthop Surg. 2010;18(7):417–25.
3. Russell DF, Ferdinand RD. Review of the evidence: surgical management of 4th and 5th tarsometatarsal joint osteoarthritis. Foot Ankle Surg. 2013;19(4):207–11.
4. Verhoeven N, Vandeputte G. Midfoot arthritis: diagnosis and treatment. Foot Ankle Surg. 2012;18(4):255–62.
5. Zonno AJ, Myerson MS. Surgical correction of midfoot arthritis with and without deformity. Foot Ankle Clin. 2011;16(1):35–47.

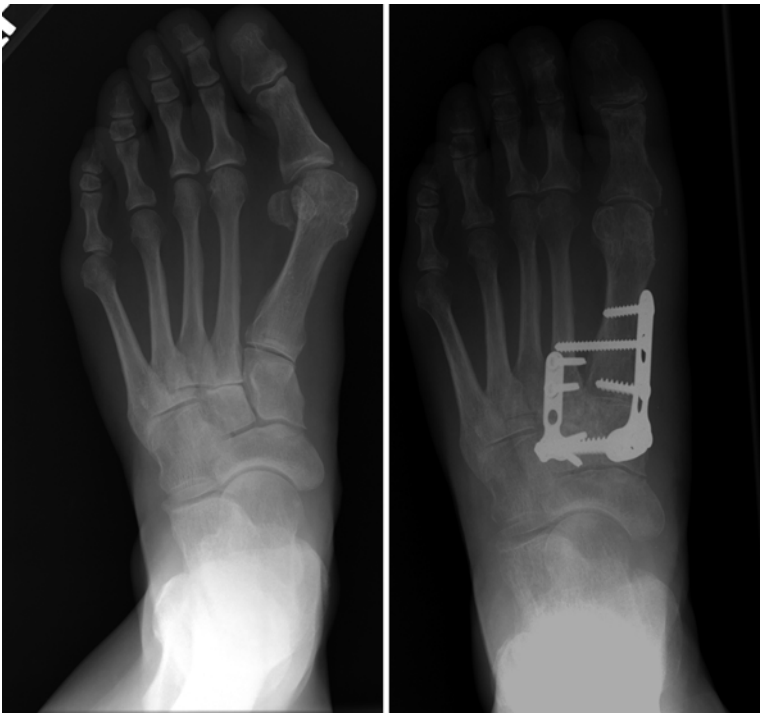

Fig. 3 A Lapidus and 2nd TMT arthrodesis was performed in this patient who presented with complaints of hallux valgus and midfoot pain with radiographic evidence of midfoot DJD. The patient had osteopenic bone and therefore plate fixation was chosen

2 Kohler's Disease

Take-Home Message

- Pediatric avascular necrosis of the navicular of unknown etiology.
- Boys preferentially affected.
- 25 % can be bilateral.
- Usually self-limiting with favorable prognosis, surgery is not indicated.
- Immobilization with short leg walking cast is indicated for activity-related symptoms.
- Immobilization decreases duration of symptoms.

Definition

- Avascular necrosis of the navicular bone of unclear etiology. Occurs in pediatric population. Patients usually present with pain (dorsomedial), swelling, and warmth/redness and limp.
- However, some patients are asymptomatic.

Fig. 4 Extended midfoot arthrodesis with concomitant medial slide calcaneal osteotomy was required in this patient who presented with midfoot arthritis and secondary hindfoot valgus deformity. Note the restoration of the longitudinal arch in the postoperative radiograph

- More common in boys (up 80 % of cases).
- 25 % of cases are bilateral.

Etiology

- Unknown

Pathophysiology

- Blood supply: the central 1/3 of the navicular is a watershed area → avascular necrosis
- Late ossification → predisposition to injury and mechanical compression

Radiography

- Foot X-ray
  - Active disease: sclerosis, fragmentation, and flattening of navicular
  - Post resolution: bone remodeling and reconstitution, asymptomatic deformity can persist

Treatment

- Usually self-limiting with good prognosis. Symptoms usually associated with activities.

Nonoperative

- NSAIDs, activity modification (eliminate impact)
- Shoe insert orthotics (accommodative)
- Immobilization with short leg walking cast
  - Indication: activity-related pain and failure of above modalities

Operative

- No indication for surgery

Complications

- Very good prognosis without post-resolution sequela. Deformity is usually asymptomatic.

Bibliography

1. Borges JL, Guille JT, Bowen JR. Köhler's bone disease of the tarsal navicular. J Pediatr Orthop. 1995;15(5):596–8.
2. DiGiovanni CW, Patel A, Calfee R, Nickisch F. Osteonecrosis in the foot. J Am Acad Orthop Surg. 2007;15(4):208–17.
3. Tsirikos AI, Riddle EC, Kruse R. Bilateral Köhler's disease in identical twins. Clin Orthop Relat Res. 2003;409:195–8.

3 Sinus Tarsi Syndrome

Take-Home Message

- Sinus tarsi syndrome presents as lateral heel pain that is relieved by local anesthetic injection into sinus tarsi and associated with feeling of instability.
- Highly associated with ankle inversion injuries.
- MRI and arthroscopy reveal inflammatory changes and partial ligamentous tear.
- Nonoperative management is the first-line treatment: serial local anesthetic/corticosteroid injections are effective.
- Favorable results for both arthroscopic and open excision and debridement.

Definition

- Sinus tarsal syndrome (STS) is a clinical entity that represents local pain in the lateral heel over sinus tarsi – located between the talus and the calcaneus.
  - Pain that is relieved by local anesthetics/corticosteroid injection.
  - Associated with hindfoot instability.
- Canalis tarsi syndrome is a variant of STS → medial side pain

Etiology

- Anatomy: The sinus tarsi is an anatomic space → bounded by inferior talus, the superior aspect of the calcaneus, posterior subtalar facet, and the calcaneonavicular joint anteriorly.
  - Medially continuous with the tarsal canal
  - Space filled with fat and contains vessels and ligaments
- The true etiology of STS is unknown, although several theories have been postulated → posttraumatic fibrosis, synovial hyperplasia, hemosiderin deposition, inflammatory response, compression of herniated synovial membrane, and proprioceptive disorder.
- There is high association with previous ankle inversion/supination injuries and independent of lateral ankle ligament complex rupture or osteochondral lesion.

Pathophysiology

- Similar to the etiology, the pathophysiology of STS is poorly understood.
- Related to posttraumatic ligamentous injury, inflammatory changes, and instability.

Radiography

X-Ray

Normal in most cases. Stress radiography may demonstrate instability of the subtalar joint, although this is difficult to demonstrate. Clinical laxity to varus stress with a normal stress X-ray of the ankle is suggestive of subtalar instability.

Subtalar Arthrogram

- Demonstrates a saclike anterior bulge of the capsule

MRI

- Visualize ligament tears, synovial thickening, and fibrosis. Loss of sinus tarsi fat is a useful objective finding.

Classification

- There is no classification for this entity

Treatment

Nonoperative

- NSAIDs, ankle/hindfoot bracing, physical therapy (peroneal strengthening and proprioception to minimize instability)
- Serial local anesthetics/corticosteroid injections
  - Reports of complete resolution

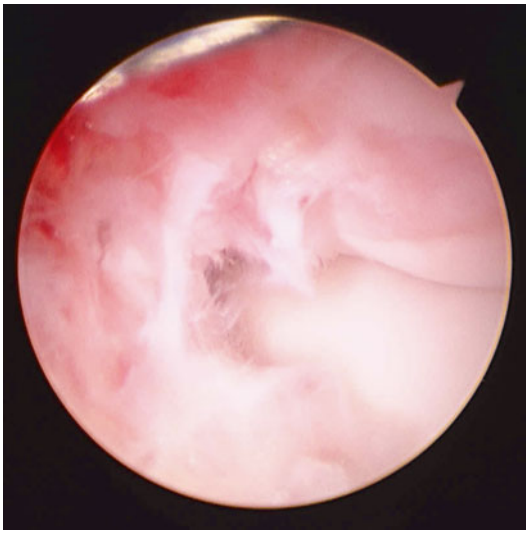

Fig. 5 Subtalar arthroscopy demonstrated synovitis and soft tissue impingement in a patient with sinus tarsi syndrome

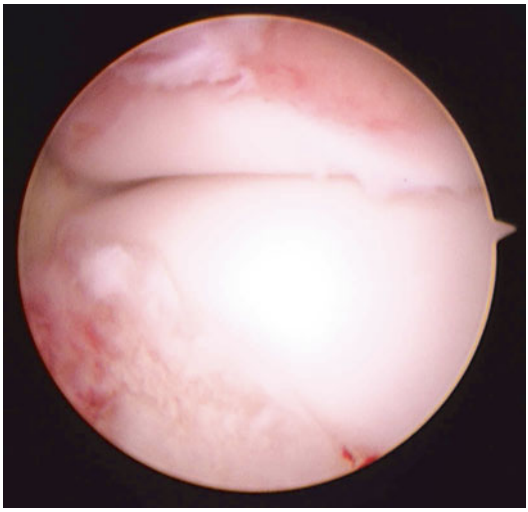

Fig. 6 Post-debridement of the same patient demonstrating removal of the offending tissue that theoretically allows impingement free motion of the subtalar joint and mechanical excision of the offending synovitis

Operative

- Arthroscopy
  - In a level IV study, arthroscopy identified pathologies in the subtalar joints of patients with STS → including partial tear of Interosseous talocalcaneal ligament (ITCL), cervical ligament (CL), synovitis, arthrofibrosis, and soft tissue impingement (Fig. 5).
    - Treatment of these pathologies led to improved pain and function.
    - Treatment included synovectomy and debridement (Fig. 6).

- Open surgical excision/debridement.
- Concomitant instability must be addressed if present. Reconstructive procedures that cross the subtalar joint are indicated to improve subtalar instability as opposed to an anatomic repair (Brostrom).
- Subtalar arthrodesis is a salvage operation in patients who have failed prior surgical attempts at joint-sparing procedures.

Complications

- Persistent pain is the most common complication with debridement. Nonunion can occur with an arthrodesis.

Bibliography

1. Frey C, Feder KS, DiGiovanni C. Arthroscopic evaluation of the subtalar joint: does sinus tarsi syndrome exist? Foot Ankle Int. 1999;20:185–91.
2. Kuwada GT. Long-term retrospective analysis of the treatment of sinus tarsi syndrome. J Foot Ankle Surg. 1994;33:28–9.
3. Lee KB, Bai LB, Park JG, Song EK, Lee JJ. Efficacy of MRI versus arthroscopy for evaluation of sinus tarsi syndrome. Foot Ankle Int. 2008;29: 1111–6.
4. Lee KB, Bai LB, Song EK, Jung ST, Kong IK. Subtalar arthroscopy for sinus Tarsi syndrome: arthroscopic findings and clinical outcomes of 33 consecutive cases. Arthroscopy. 2008;24:1130–4.
5. Zwipp H, Swoboda B, Holch M, Maschek HJ, Reichelt S. Sinus tarsi and canalis tarsi syndromes. A post-traumatic entity. Unfallchirurg. 1991;94:608–13.

4 Coalition

Take-Home Message

- Congenital fusion of two tarsal bones which could be fibrous, cartilaginous, or osseous (most commonly calcaneonavicular (CN) > talocalcaneal).
- Can lead to rigid flatfoot deformity → spastic peroneal flatfoot.
- Onset of symptoms corresponds with timing of ossification of coalition.
- Can be a cause of recurrent ankle sprains.
- Nonoperative management for asymptomatic – accommodative orthotics.
- Operative management – surgical resection with interposition (tendon or bone wax) for CN or talocalcaneal (<50 % involved). Triple arthrodesis for revision (CN) or subtalar fusion (>50 % talocalcaneal or revision)

Definition

- Tarsal coalition is a congenital abnormal union of two tarsal bones at variable levels
- Leads to rigid flatfoot deformity → peroneal spastic flatfoot

Etiology

- Presumed lack of differentiation of mesenchymal tissue, resulting in failure of normal joint articulation.
- Genetic predisposition

Pathophysiology

- Abnormal tissue bridge between two tarsal bones
  - Fibrous coalition
  - Cartilaginous coalition
  - Osseous coalition
- Two most common areas involved are → calcaneonavicular > talocalcaneal
- Onset of symptoms corresponds with timing ossification of coalition, calcaneonavicular (8–12), and talocalcaneal (12–16).
  - Sinus tarsi, medial hindfoot, and peroneal tendons
  - Persistent pain following ankle sprain
- Rigid flatfoot deformity: restricted subtalar motion results in
  - The subtalar joint lacks the ability to invert and create a normal longitudinal arch. The chopart joints are forced to develop in an abducted position with a pes planus deformity.
  - The peroneal tendons develop in a shortened fashion which accounts for the "spasm" that is felt with attempted inversion.
  - Subtalar arthrosis (late finding)

Radiography

- AP, lateral (standing), 45-degree oblique, and Harris axial X-ray views
  - 45-degree oblique view → calcaneonavicular (Fig. 7)
  - Lateral view
    - Calcaneonavicular → elongated anterior process of calcaneus ("anteater sign")
    - Talocalcaneal → talar beaking (Fig. 8)
  - Harris heel view → talocalcaneal → irregular middle facet joint
- CT scan
  - Better characterize size and extent of coalition

Fig. 7 Oblique radiograph of a patient with a fibrous calcaneonavicular coalition. The anteater sign is evidenced by the elongated anterior process with the associated flattening (*arrow*)

- MRI
  - Evaluate fibrous or cartilaginous coalition (Fig. 9)

Classification

On the basis of anatomic location

- Talocalcaneal
  - Anterior facet
  - Middle facet (most common)
  - Posterior facet

On the basis of completeness of ossification

- Synostosis: completely ossified bar, associated with fibular hemimelia and proximal focal femur deficiency and Apert syndrome.
- Synchondrosis: partially cartilaginous bar.
- Syndesmosis: fibrous bar.

Fig. 8 Lateral radiograph demonstrating talar beaking (*arrow*) in a patient with a talocalcaneal coalition. The prominence is directed superior and distal

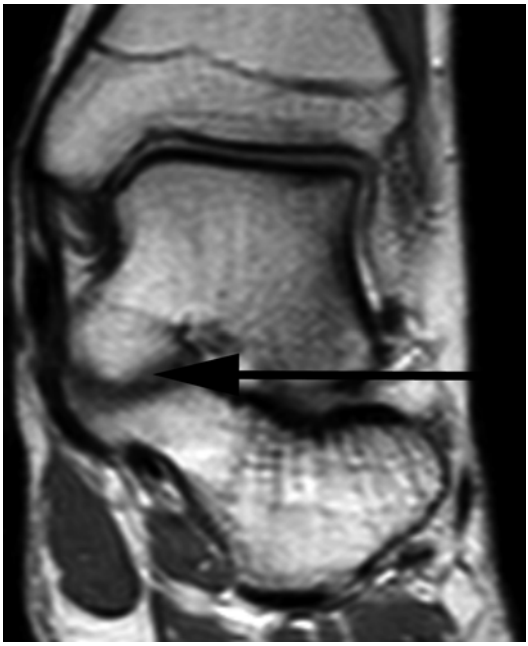

Fig. 9 Coronal T1 MRI of a nonosseous talocalcaneal coalition (*arrow*). There is a lack of bony continuity that distinguishes this from an osseous coalition. The middle facet is irregular with a very thin fibrous bridge present

Treatment Most coalitions are asymptomatic.

Nonoperative

- Observation for asymptomatic
- Short leg walking cast immobilization
- Accommodative full length orthotic

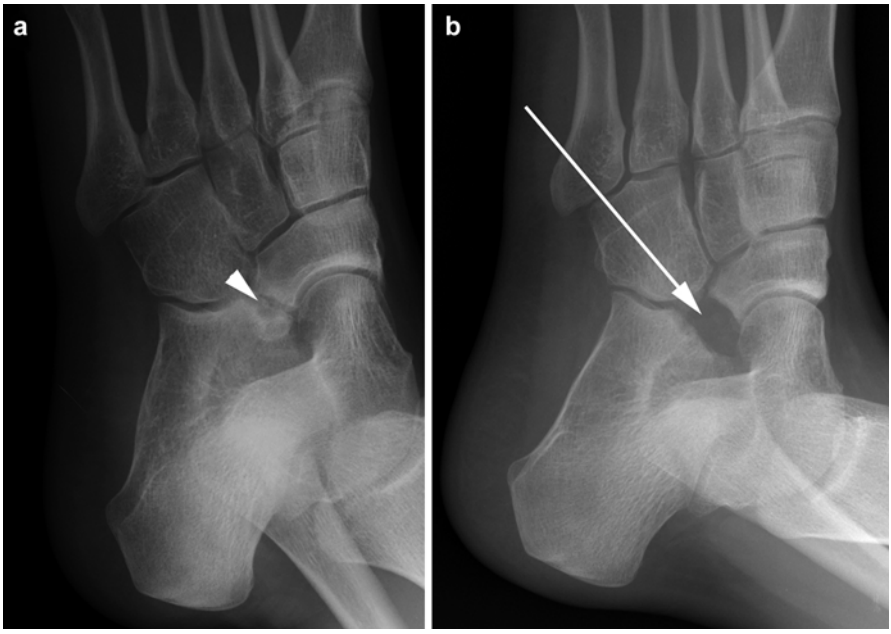

Fig. 10 Preoperative appearance (**a**) of a CN coalition (*arrowhead*) and the appropriate postoperative appearance after resection (**b**). Note how the resection removes a block of bone from the coalition which should create a square defect (*arrow*)

Operative

- Calcaneonavicular
  - Coalition resection of a rectangular 1 cm block (Fig. 10)
  - Interposition: bone wax or EDB (increases risk of wound complications)
- Talocalcaneal
  - Coalition resection with interposition (bone wax or split FHL)
    - Gold standard indication is lacking.
      - <50 % involvement of middle facet
      - Coalition surface area <50 % of the surface area of the posterior facet
      - <16° of valgus
  - Subtalar arthrodesis
    - >50 % involvement, subtalar arthrosis, and revision (Fig. 11)
- Triple arthrodesis
  - Any coalition with multiple joint arthrosis, revision, or severe hindfoot valgus or abduction

Fig. 11 Preoperative lateral radiograph (**a**) of a talocalcaneal coalition with associated talar beaking. Postoperative lateral radiograph (**b**) following coalition resection, subtalar arthrodesis, and excision of the talar beaking

Complications

- Hindfoot joint arthritis
- Persistent pain and deformity

Bibliography

1. Cass AD, Camasta CA. A review of tarsal coalition and pes planovalgus: clinical examination, diagnostic imaging, and surgical planning. J Foot Ankle Surg. 2010;49(3):274–93. doi:10.1053/j.jfas.2010.02.003.
2. Lemley F, Berlet G, Hill K, Philbin T, Isaac B, Lee T. Current concepts review: Tarsal coalition. Foot Ankle Int. 2006;27(12):1163–9.
3. Thorpe SW, Wukich DK. Tarsal coalitions in the adult population: does treatment differ from the adolescent? Foot Ankle Clin. 2012;17(2):195–204. doi:10.1016/j.fcl.2012.03.004.
4. Zaw H, Calder JD. Tarsal coalitions. Foot Ankle Clin. 2010;15(2):349–64. doi:10.1016/j.fcl.2010.02.003.